

White matter structural connectivity underlying semantic processing: evidence from brain damaged patients

Zaizhu Han,¹ Yujun Ma,¹ Gaolang Gong,¹ Yong He,² Alfonso Caramazza^{3,4} and Yanchao Bi²

1 State Key Laboratory of Cognitive Neuroscience and Learning, Beijing Normal University, Beijing 100875 China

2 State Key Laboratory of Cognitive Neuroscience and Learning & IDG/McGovern Institute for Brain Research, Beijing Normal University, Beijing 100875, China

3 Department of Psychology, Harvard University, Cambridge, MA 02138, USA

4 Centre of Mind/Brain Sciences (CIMeC), University of Trento, I-38122 Trento, Italy

Correspondence to: Yanchao Bi,
State Key Laboratory of Cognitive Neuroscience and Learning &
IDG/McGovern Institute for Brain Research,
Beijing Normal University,
Beijing 100875, China
E-mail: ybi@bnu.edu.cn

Widely distributed brain regions in temporal, parietal and frontal cortex have been found to be involved in semantic processing, but the anatomical connections supporting the semantic system are not well understood. In a group of 76 right-handed brain-damaged patients, we tested the relationship between the integrity of major white matter tracts and the presence of semantic deficits. The integrity of white matter tracts was measured by percentage of lesion voxels obtained in structural imaging and mean fractional anisotropy values obtained in diffusion tensor imaging. Semantic deficits were assessed by jointly considering the performance on three semantic tasks that vary in the modalities of input (visual and auditory stimuli) and output (oral naming and associative judgement). We found that the lesion volume and fractional anisotropy value of the left inferior fronto-occipital fasciculus, left anterior thalamic radiation, and left uncinate fasciculus significantly correlated with severity of impairment in all three semantic tasks. These associations remained significant even when we controlled for a wide range of potential confounding variables, including overall cognitive state, whole lesion volume, or type of brain damage. The effects of these three white matter tracts could not be explained by potential involvement of relevant grey matter, and were (relatively) specific to object semantic processing, as no correlation with performance on non-object semantic control tasks (oral repetition and number processing tasks) was observed. These results underscore the causal role of left inferior fronto-occipital fasciculus, left anterior thalamic radiation, and left uncinate fasciculus in semantic processing, providing direct evidence for (part of) the anatomical skeleton of the semantic network.

Keywords: semantic network; DTI; connectome; brain-damaged patient

Abbreviations: ATR = anterior thalamic radiation; IFOF = inferior fronto-occipital fasciculus; MMSE = Mini-Mental State Examination; UF = uncinate fasciculus

Introduction

The semantic system supports a large range of human cognitive processes including language, object recognition, object use and

reasoning. Decades of neuroimaging and neuropsychological research on the neural basis of semantic processing has led to the consensus view that widely distributed brain regions are involved, including the middle temporal lobe, ventral temporal cortex,

inferior parietal lobe, middle and inferior frontal gyri, medial prefrontal cortex and posterior cingulate (Dronkers *et al.*, 2004; Martin, 2007; Patterson *et al.*, 2007; Binder *et al.*, 2009; Mahon and Caramazza, 2009; Wei *et al.*, 2012).

How are these multiple brain regions anatomically connected together to form the semantic network? The crucial role of connections in higher functions has long been recognized and has especially been highlighted in research focusing on disconnection syndromes (Geschwind, 1965; see review in Catani and ffytche, 2005). Only in recent years, however, have methodological advances allowed for more direct examination of the relationship between specific white matter tracts and semantic processing *in vivo*, but no clear consensus has emerged. Diffusion tensor imaging studies in patients with semantic dementia or a semantic variant of primary progressive aphasia have shown that compared with controls, these patients have reduced integrity in a wide range of white matter tracts including both ventral [inferior fronto-occipital fasciculus (IFOF), inferior longitudinal fasciculus and uncinate fasciculus] and dorsal fasciculi [arcuate fasciculus, cingulum gyrus and superior longitudinal fasciculus], in both hemispheres (Acosta-Cabronero *et al.*, 2010, 2011; Schwindt *et al.*, 2013). It remains unclear, however, which of the various tracts affected by the relevant pathology are causally implicated in the observed semantic deficits. Studying healthy elderly individuals, de Zubicaray *et al.* (2011) reported that the fractional anisotropy values of voxels along the left IFOF and uncinate fasciculus significantly correlated with subjects' semantic performance. Other studies targeted specific white matter tracts and reported effects of the left IFOF using intraoperative electrical stimulation (Duffau *et al.*, 2002, 2005, 2009; Duffau, 2008), or effects of fibres going through the extreme capsule in studies using diffusion tensor imaging, including fractional anisotropy, with healthy (Saur *et al.*, 2008, 2010) and brain damaged subjects (Rolheiser *et al.*, 2011). These studies are constrained by the specific white matter tracts they targeted without the opportunity to reveal effects of other tracts. More importantly, they used verbal semantic tasks such as oral picture naming, sentence comprehension or property judgement, and thus the observed effects may be attributable to cognitive components beyond the semantic system such as lexical retrieval (and syntax in the case of sentence processing) (Caramazza and Hillis, 1990; Cloutman *et al.*, 2009). In summary, studies with comprehensive examination of white matter tracts and semantic tasks are warranted to clarify the noted discrepancies and provide a more complete picture of the semantic network.

We adopted a generalized voxel-wise lesion analysis approach (Bates *et al.*, 2003; Rudrauf *et al.*, 2008) and investigated the anatomical connectivity supporting semantic processing by studying the relationship between the integrity of major white matter tracts and semantic deficits in a group of 76 right-handed subjects with brain damage. For the anatomical side of the equation, we measured the percentage of lesion voxels (structural imaging) and the mean fractional anisotropy (diffusion tensor imaging) of each major tract; for the cognitive side of the equation, we measured each patient's semantic deficit by considering jointly performance on three semantic tasks that vary in the modalities of stimulus input (visual and auditory stimuli) and response output (oral

naming and associative judgement). Observed associations between damage to white matter tracts and semantic deficits were further validated by statistically removing effects of potential confounding factors such as general cognitive state, whole lesion volume, the effect of semantics-relevant grey matter regions, and performance on two control tasks.

Materials and methods

Participants

Patients with brain damage and healthy controls took part in the experiments. Behavioural data were collected for both subject groups using identical procedures. Participants were all native Chinese speakers, were paid for their participation, and had provided informed written consent. The study was approved by the Institutional Review Board of the National Key Laboratory of Cognitive Neuroscience and Learning, Beijing Normal University.

Patients

Eighty-three patients with brain damage (68 males) from the China Rehabilitation Research Centre who were willing to participate in the study were recruited with the following inclusion criteria: no previous brain injury; no other neurological or psychiatric disease such as alcohol abuse or severe depression; at least 1 month post-onset; able to follow task instructions; and right-handed (Edinburgh Handedness Inventory, Oldfield, 1971). Seven patients were not included in the analyses due to excessive head movement (one patient) or normalization failure (six patients). The majority of the remaining 76 patients (61 males) patients suffered from stroke ($n = 66$). Patients with other aetiologies were also included to maximize lesion coverage (six traumatic brain injury, one atrophy, one electronic shock, one gas poisoning and one unknown). The possible influence of aetiology was considered by carrying out analyses only on the stroke cases and treating aetiology as a variable. The mean age was 47 years [standard deviation (SD) = 13; range: 20–76 years] and the mean formal education was 13 years (SD = 3; range: 2–19 years). The Chinese version of the Mini-Mental State Examination (MMSE, Folstein *et al.*, 1975) was given as a measure of general cognitive state (mean = 21.54; SD = 8.42; range = 0–30) (Supplementary Table 1).

Healthy participants

Fifty-one healthy control subjects (27 males) without neurological or psychiatric illness participated in the study. The subjects' mean age was 50 years (SD = 11; range: 26–72 years) and their mean years of formal education was 13 (SD = 4; range: 6–22 years). All were right-handed. Mean score on MMSE was 28.51 (SD = 1.34; range: 24–30) (Supplementary Table 2).

Behavioural data

Semantic processing ability was assessed by jointly considering three classical tasks that all involve the object semantics component yet vary in modalities of input and output: object oral picture naming, object oral sound naming, and object picture associative matching (see similar approach in Jefferies *et al.*, 2008; Wei *et al.*, 2012). We considered both the conjunction results of the three semantic tasks and their composite. Each task included a variety of common objects (see below for details) and was run in separate sessions using the DMDX program (Forster and Forster, 2003) on a PC. For each task, item

presentation order was randomized and was identical across subjects. There was a 60 s response deadline. Participants were tested individually in a quiet room. Each session lasted no more than 2 h; pauses for rest were included upon request.

Oral picture naming

One hundred photographs of objects were used, 20 items from each of five categories: animals, tools, common artefacts, fruits and vegetables, and large non-manipulable objects. Participants were instructed to name each object. The first complete response was scored for each item.

Oral sound naming

The test included 36 items: 10 animal sounds (e.g. barking of a dog), six tool sounds (pounding of a hammer), 10 sounds of common artefacts (ringing of a telephone), and 10 other types of sounds (sound of thunder). Participants heard the target sound through earphones and were required to speak out the name of the objects that produced the sound (dog, hammer, telephone, thunder). The first complete response was scored for each item.

Picture associative matching

This task had the same format as the Pyramids and Palm Trees Test (Howard and Patterson, 1992), with each trial containing three photographed objects on a touch screen. Participants judged which of the two bottom photographs (e.g. orange, onion) was semantically closer to the top photograph (e.g. banana) by pressing the corresponding photograph on the touch screen. There were 50 trials in total, with 10 from each of the five categories in the oral picture-naming test. The three pictures in each trial were always from the same semantic category.

Control tasks

To assess the (relative) specificity of potential semantics-related fibres, we included two control tasks: a language task that requires minimal semantic processing, oral repetition; and a set of number tasks that do not involve object semantics. The oral repetition task included eight words and four sentences and the participants were asked to repeat the words/sentences they heard over earphones. The number task set included seven exact calculation questions (two addition, two subtraction, two multiplication, and one division) and five number questions (e.g. how many months are there in a year?).

Imaging data

Patients were scanned at the China Rehabilitation Research Centre with a 1.5T GE SIGNA EXCITE scanner. We collected three types of images: (i) high resolution 3D T₁-weighted images; (ii) FLAIR T₂-weighted images; and (iii) diffusion-weighted images. The 3D images were T₁-weighted 3D MPRAGE images on the sagittal plane with parameters: matrix size = 512 × 512, voxel size = 0.49 × 0.49 × 0.70 mm³, repetition time = 12.26 ms, echo time = 4.2 ms, inversion time = 400 ms, field of view = 250 × 250 mm², flip angle = 15°, slice number = 248 slices. The FLAIR T₂ images were FLAIR T₂-weighted images on the axial plane with parameters: matrix size = 512 × 512, voxel size = 0.49 × 0.49 × 5 mm³, repetition time = 8002 ms, echo time = 127.57 ms, inversion = 2 s, field of view = 250 × 250 mm², flip angle = 90°, slice number = 28 slices. Diffusion-weighted imaging had two separate sequences with different diffusion weighting direction sets so that 32 directions were covered in total. The first acquisition had the following parameters: 15 diffusion weighting directions, matrix size = 128 × 128,

voxel size = 1.95 × 1.95 × 2.6 mm³, repetition time = 13 000 ms, echo time = 69.3 ms, inversion time = 0 s, field of view = 250 × 250 mm², flip angle = 90°, slice number = 53 slices. The other acquisition had the same parameters except that it included 17 different directions. The first two volumes were b0 volumes and the b-value of other volumes was 1000 s/mm² in each sequence. All the sequences except for FLAIR T₂ images were scanned twice to improve the quality of images.

Behavioural data preprocessing

As the patient group showed considerable variation in demographic properties (e.g. age, gender, education; Supplementary Table 1), 'raw' accuracy scores on the behavioural tasks might not meaningfully reflect the degree of deficit. We adopted a standardization method proposed by Crawford and Garthwaite (2006), where patients' behavioural scores are corrected by considering the performance distribution in the healthy population and transforming each patient's raw accuracy score into a standardized 't' score, with the results using the raw accuracy scores (with demographic variables partialled out) presented in Supplementary Tables 3 and 4. We chose the standardized t-score because the regression models based on a healthy subjects sample more accurately reflect the effects of demographic variables on the particular behavioural task without confounds of the lesion variable. Such an approach is also more consistent with the convention of comparing individuals to normative comparison standards in neuropsychology (Crawford and Garthwaite, 2006). Using this approach, for each task we first established a regression model on the basis of the properties of the healthy control group ($n = 51$), with the dependent variable being their accuracy scores and the predictors including age, gender and education. A predicted accuracy score for each patient was acquired by introducing his or her demographic information into the model, and it was used to generate a discrepancy value ($Discrepancy_{patient}$) (i.e. observed accuracy – predicted accuracy). A corrected standard error of estimate for each patient ($SE_{patient}$) was obtained using the following formula:

$$SE_{patient} = S_{Y.X} \sqrt{1 + \frac{1}{N} + \frac{1}{N-1} \sum r^{ij} Z_{io}^2 + \frac{2}{N-1} \sum r^{ij} Z_{io} Z_{jo}}$$

where $S_{Y.X}$ and N are the standard error and sample size for the control group; r^{ii} and r^{ij} are main diagonal and off-diagonal elements of the inverted correlation matrix for the k predictor variables ($k = 3$, i.e. age, education, gender); and z_o (z_{1o}, \dots, z_{ko}) are the z-scores of the patient's accuracies on the predictor variables. The patient's t-score was then computed: $t\text{-score}_{patient} = Discrepancy_{patient} / SE_{patient}$ (Crawford and Garthwaite, 2006). The z-transformed t-scores for the calculation and number question tasks were averaged as a number task score. Besides the t-score for each task, for each patient we also calculated a semantic composite score by averaging the z-transformed t-scores on the three critical semantic tasks, as an overall index of semantic processing ability. Both the semantic composite score and the three individual semantic tasks were considered in our analyses below.

Imaging data preprocessing

Our analyses considered two indices reflecting the severity of brain damage: lesion status obtained from structural MRI and fractional anisotropy obtained from diffusion MRI. The lesion index reflects physical damage to voxels, in either white or grey matter. It is a dichotomous variable, scoring a given voxel as intact or lesioned, and is considered a classical indicator of lesion severity (Bates et al., 2003). Fractional anisotropy is one of the most widely used variables to evaluate the

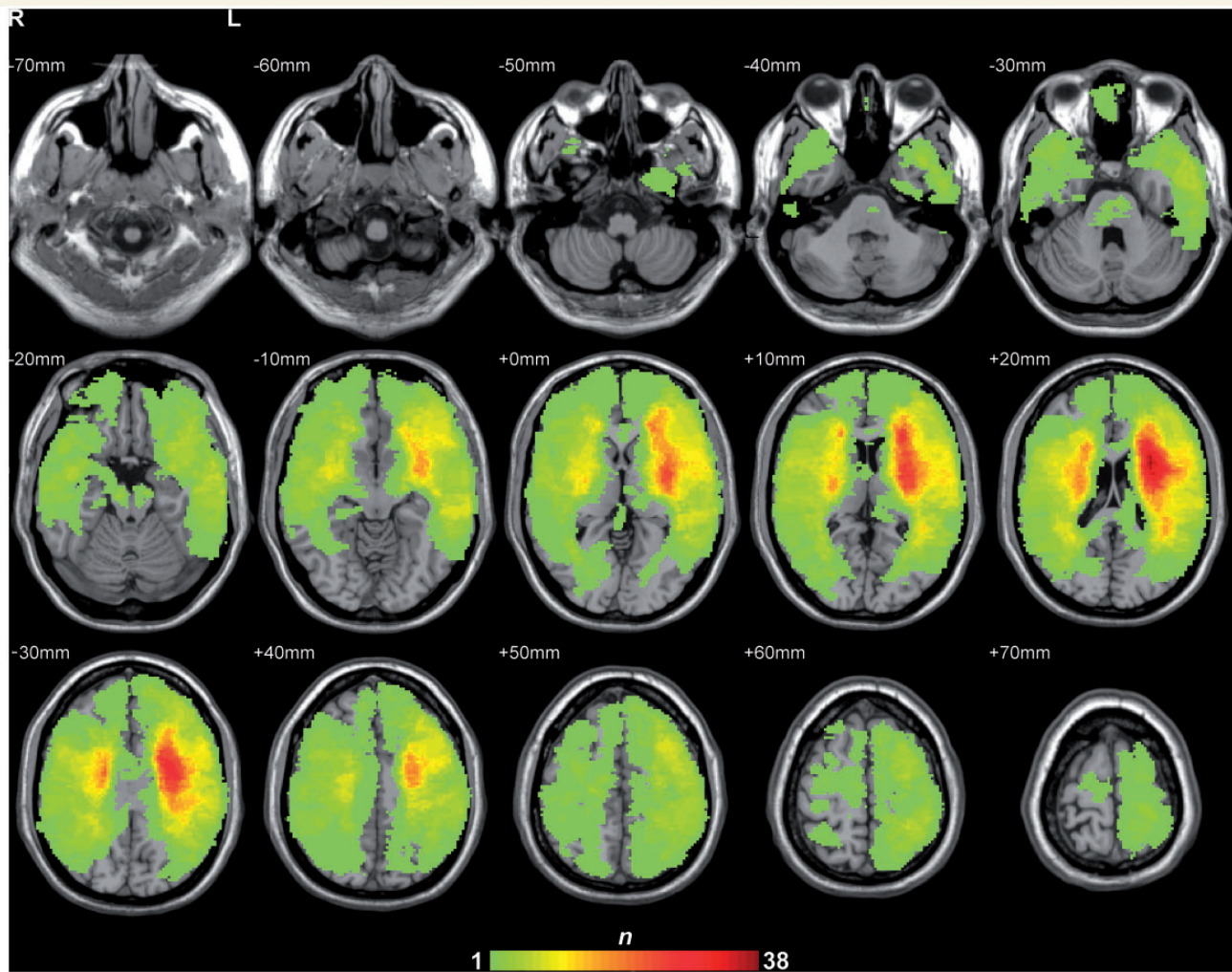


Figure 1 Lesion overlap map of the 76 patients (the n value of each voxel denotes the number of patients with lesion).

integrity of white matter tracts in a given voxel for patients and healthy populations (Rolheiser *et al.*, 2011; Wilson *et al.*, 2011), reflecting fibre density, axonal diameter, and myelination in white matter (Basser and Pierpaoli, 1996). In our data set, each voxel in each patient had a lesion value (categorical variable) from the lesion map (Fig. 1) and a fractional anisotropy value (continuous variable) from the normalized fractional anisotropy map. It has been shown that lesioned brain regions have lower fractional anisotropy values than intact ones (Kim *et al.*, 2005), thus these two variables are correlated to a certain degree. Nonetheless, fractional anisotropy analyses may provide additional information about the effects of the intact voxels in a given tract, which may in turn be affected by lesions in that tract. In our analyses we considered lesion percentage and fractional anisotropy variables separately to check for convergence and then their relative contributions were specifically examined by means of partial correlation. The lesion and fractional anisotropy maps were derived using the following procedures.

Structural magnetic resonance imaging data

For the 3D imaging data, we first co-registered each of the two sequences on the same native space using tri-linear interpolation method implemented in SPM5 (<http://www.fil.ion.ucl.ac.uk/spm/software/>

spm5) and then averaged them. The FLAIR T₂ images were co-registered and resliced to the native space of the averaged 3D images with tri-linear interpolation method in SPM5. Two trained personnel manually drew each patient's lesion contour on averaged 3D images slice by slice, visually referring to FLAIR T₂ images. This lesion-drawing procedure was supervised by an experienced radiologist. Each patient's structural images were resliced into $1 \times 1 \times 1 \text{ mm}^3$ voxel size, and then manually registered into Talairach space via the '3D Volume Tools' in BrainVoyager QX v2.0 (www.brainvoyager.com). We used the ANTs software package (Advanced Normalization Tools, <http://www.picsl.upenn.edu/ANTS/>) to extract the affine transformation matrix between native and Talairach spaces, which was employed to register and transform the lesion description into Talairach space using the 'WarpImageMultiTransform' program. The lesion description was transformed into the MNI space.

Diffusion magnetic resonance imaging data

For the diffusion-weighted imaging data, for each patient we first merged each of the 15 directions and 17 directions paired sequences into one single 4D nifti-1 format file and merged diffusion-weighted gradient tables of the two sequences. We then executed the following steps using a pipeline tool, PANDA (Cui *et al.*, 2013) (<http://www>.

nitrc.org/projects/panda/), BET: skull removal; Eddycorrect: correction of eddy current distortion; DTIFIT, build diffusion tensor models. After obtaining the fractional anisotropy maps of each patient, we registered them with the FMRIB fractional anisotropy template in MNI space using ANTs (version 1.9). The normalization included two steps: linear rigid affine and non-linear transform registration. In linear affine transform, one affine transform.txt file for each participant was obtained using 'ANTs' program, and then the 'WarpImageMultiTransform' program was executed to produce the fractional anisotropy map in MNI space. In non-linear transform, a shell script 'buildtemplate' was used to obtain more fine-grained normalized fractional anisotropy map of each patient in MNI space.

Brain-behaviour mapping analysis

To identify the major brain pathways responsible for object semantics processing, we examined the relationship between the integrity of the major tracts (measured by lesion percentage and fractional anisotropy values) and degree of object semantics impairment. Specifically, we (i) correlated the lesion volume (percentage of voxels with lesion) and the mean fractional anisotropy value of each tract and object semantics performance; (ii) examined the relationship between lesion and fractional anisotropy measures in accounting for semantic behaviour; and (iii) entered the properties of the tracts observed in the correlation analyses into regression models to predict semantic performance. We then consolidated the effect of the observed semantics-related tract effects by considering other potential contributing factors including overall lesion volume, cognitive state (MMSE score), types of brain damage, relevant grey matter lesions, and control tasks performance.

Tract-semantic mapping

To identify major white matter tracts, we adopted a widely used human brain white-matter template, the 'JHU white-matter tractography atlas' from FSL (<http://www.fmrib.ox.ac.uk/fsl/data/atlas-descriptions.html#wm>), which contains 20 main white matter bundles and has three individual sets of sub-templates with different probability levels in the probability tractography map: 0%, 25% and 50%, reflecting the minimal percentage of subjects having a tract identified on each voxel on the basis of 28 normal subjects (mean age 29 years; 17 males, 11 females). The 0% map contains a relatively large proportion of grey matter or peripheric white matter; the 50% map contains only 12 tracts without bilateral uncinate fasciculus, cingulum gyrus, cingulum (hippocampus) (cingulum hippocampus), and superior longitudinal fasciculus (temporal part). We chose to use the 25%-threshold sub-template, which contains 20 major tracts (Table 1). In order to rule out the possibility that any potential effects observed with the tracts in the 25% maps were driven by the relatively high grey matter or peripheric white matter inclusion, analyses were also carried out on the 50% map. The results of this additional analysis were highly convergent with those for the 25% maps (data not shown). Each analysis was also carried out only on the stroke patients ($n = 66$) in order to rule out potential confounding effects of lesion type (Table 2 and Supplementary Table 5).

Lesion-behaviour correlation

Three tracts (left cingulum gyrus, left cingulum hippocampus and right cingulum hippocampus) had lesions in fewer than five patients (Table 1) and were excluded from our lesion analysis. For each of the remaining 17 tracts, the lesion percentage (number of voxels with lesion divided by total number of voxels in the tract) was correlated with patients' scores in each of the three semantic tasks, as well as the semantic composite score. The results were adjusted for the 17

tracts with the Bonferroni correction method ($P < 0.00294$, corrected $P < 0.05$). Tracts showing significant correlation with all three semantic tasks were considered to be semantic-relevant fibres. Those associated with only one or two tasks are also reported.

Fractional anisotropy-behaviour correlation

For each of the 20 tracts in the template the mean fractional anisotropy value was obtained by averaging the fractional anisotropy values of all voxels in the tract. The mean fractional anisotropy value was then correlated with the scores on each semantic task and also the semantic composite scores across patients. The Bonferroni correction method ($P < 0.0025$, corrected $P < 0.05$) was implemented (on 20 white matter tracts).

We further evaluated whether fractional anisotropy values reveal information in addition to extent of lesion. In other words, we wanted to know whether the effects of a particular tract in semantic processing are fully captured by lesion extent or are also attributable to the 'efficiency' of the intact voxels in that tract. One may also imagine that a lesion affects a voxel's function in a continuous manner, which would not be reflected by the discrete lesion variable but by the fractional anisotropy variable. We thus: (i) calculated partial correlations between semantic composite scores and the mean fractional anisotropy values, with lesion percentage values as covariates; and (2) calculated the correlation between fractional anisotropy values of intact voxels (i.e. excluding the voxels with lesion) and semantic composite scores.

Assessment of unique contribution of the relevant white matter tracts with regression analyses

In those cases where multiple tracts were found to be associated with semantic processing in the above correlation analyses, we conducted multiple regression analyses on these tracts of interest to further examine their unique contribution. The dependent variable was the semantic composite scores. The predictors included either the lesion percentage or the mean fractional anisotropy value of the tract showing significant correlation in the lesion percentage-behaviour or fractional anisotropy-behaviour correlation analyses above. We specifically tested whether each tract of interest made unique contributions beyond the other tracts by using a hierarchical method, each time entering all other tracts of interest into the regression model first, then the target tract in a second step. The R^2 change of this second step would thus indicate whether the target tract had effects over and above the other tracts.

Testing the semantic-specificity of the observed tracts

To examine whether the observed semantics-related white matter tract results are driven by various types of potentially confounding variables, we carried out the following set of control analyses on these tracts of interest: (i) controlling for overall cognitive state and overall lesion volume; (ii) ruling out the influence of type of brain damage; (iii) considering the effects of grey matter; and (iv) examining the effects of non-semantic control tasks (oral repetition and number tasks) (Table 2). To simplify, the behavioural indexes of these analyses implemented composite scores for the three semantic tasks.

Overall cognitive state and total lesion volume

To control for the contributions of overall cognitive state and total lesion volume to semantic deficits, we carried out partial correlations between semantic composite scores and the tract lesion volumes and mean fractional anisotropy values, with patients' MMSE scores and

Table 1 Correlation coefficients between white matter tract integrity (lesion percentages and mean fractional anisotropy values) and performance on the three semantic tasks across 76 patients

| Tract | Total volume (mm ³) | Number of patients with lesion | Lesion-behavior correlation | | | Fractional anisotropy-behaviour correlation | | | | |
|---|---------------------------------|--------------------------------|-----------------------------|----------|---------|---|---------|----------|-----------|---------|
| | | | OPN | OSN | PAM | OPN | OSN | PAM | Composite | |
| 1 L anterior thalamic radiation | 8128 | 44 | -0.59*** | -0.48*** | -0.41** | -0.57*** | 0.51*** | 0.52*** | 0.44*** | 0.57*** |
| 2 R anterior thalamic radiation | 7576 | 33 | 0.32 | 0.32 | 0.2 | 0.32 | -0.39** | -0.40** | -0.15 | -0.36* |
| 3 L corticospinal tract | 5464 | 44 | -0.3 | -0.3 | -0.07 | -0.26 | 0.57*** | 0.63*** | 0.29 | 0.58*** |
| 4 R corticospinal tract | 4760 | 28 | 0.38* | 0.41** | 0.24 | 0.40** | -0.43** | -0.48*** | -0.23 | -0.45** |
| 5 L cingulum gyrus | 1552 | 4 | — | — | — | — | 0.03 | 0.12 | 0.25 | 0.15 |
| 6 R cingulum gyrus | 608 | 7 | 0.17 | 0.13 | 0 | 0.12 | -0.17 | -0.07 | 0.11 | -0.05 |
| 7 L cingulum hippocampus | 248 | 0 | — | — | — | — | 0.02 | 0.02 | 0.07 | 0.04 |
| 8 R cingulum hippocampus | 544 | 2 | — | — | — | — | -0.2 | -0.15 | 0.02 | -0.13 |
| 9 Forceps major | 5744 | 18 | 0.07 | 0.07 | 0.12 | 0.1 | -0.13 | -0.14 | -0.06 | -0.13 |
| 10 Forceps minor | 19712 | 46 | 0.01 | -0.04 | -0.11 | -0.06 | -0.03 | -0.04 | 0.19 | 0.04 |
| 11 L inferior fronto-occipital fasciculus | 5048 | 44 | -0.54*** | -0.52*** | -0.37* | -0.56*** | 0.62*** | 0.57*** | 0.44** | 0.63*** |
| 12 R inferior fronto-occipital fasciculus | 6304 | 35 | 0.33 | 0.33 | 0.21 | 0.34** | -0.36* | -0.39* | -0.16 | -0.35 |
| 13 L inferior longitudinal fasciculus | 5400 | 25 | -0.24 | -0.13 | -0.04 | -0.16 | 0.40*** | 0.34 | 0.27 | 0.39** |
| 14 R inferior longitudinal fasciculus | 3152 | 9 | 0.23 | 0.21 | 0.12 | 0.22 | -0.28 | -0.25 | -0.06 | -0.23 |
| 15 L superior longitudinal fasciculus | 9472 | 45 | -0.49*** | -0.44*** | -0.07 | -0.39** | 0.52*** | 0.51*** | 0.07 | 0.43** |
| 16 R superior longitudinal fasciculus | 7456 | 19 | 0.23 | 0.23 | 0.03 | 0.19 | -0.37* | -0.35* | -0.14 | -0.33 |
| 17 L uncinata fasciculus | 744 | 23 | -0.49*** | -0.41** | -0.35* | -0.49*** | 0.55*** | 0.51*** | 0.37* | 0.55*** |
| 18 R uncinata fasciculus | 448 | 15 | 0.26 | 0.29 | 0.14 | 0.27 | -0.34* | -0.36 | -0.17 | -0.34 |
| 19 L superior longitudinal fasciculus (temporal part) | 96 | 7 | -0.12 | -0.08 | 0.09 | -0.04 | 0.22 | 0.13 | 0.05 | 0.16 |
| 20 R superior longitudinal fasciculus (temporal part) | 72 | 6 | 0.17 | 0.16 | 0.08 | 0.16 | -0.26 | -0.3 | -0.1 | -0.26 |

L = left; R = right; OPN = oral picture naming; OSN = oral sound naming; PAM = picture associative matching; composite = composite score. Bonferroni corrected: * $P < 0.05$; ** $P < 0.01$; *** $P < 0.001$; — could not carry out this analysis due to few patients.

Table 2 Partial correlation coefficients between the white matter tract integrity of left IFOF (inferior fronto-occipital fasciculus), left ATR (anterior thalamic radiation), and left UF (uncinate fasciculus) (mean fractional anisotropy values and lesion percentages) and behavioural performances, controlling for potential confounding factors on the three tracts

| Control aspect | Control variable | Analysis type | Left IFOF | Left ATR | Left UF |
|--|--|------------------------------|-----------|--------------------|----------|
| Overall severity and total lesion volume | MMSE, total lesion volume | Lesion analysis | −0.37** | −0.25* | −0.34** |
| | | FA analysis | 0.42*** | 0.36** | 0.47*** |
| Types of brain damage | All patients: lesion type index, MMSE, total lesion volume | Lesion analysis | −0.39*** | −0.28* | −0.35** |
| | | FA analysis | 0.43*** | 0.36** | 0.46*** |
| | Only 66 stroke patients: MMSE, total lesion volume | Lesion analysis | −0.49*** | −0.34** | −0.43*** |
| | | FA analysis | 0.42*** | 0.39** | 0.42*** |
| | Only 25 patients with stroke in left hemisphere: MMSE, total lesion volume | Lesion analysis | −0.57** | −0.22 | −0.41* |
| | | FA analysis | 0.53** | 0.49* | 0.53** |
| Effect of grey matter | Lesion volume in the semantic-related gray matter regions of interest, MMSE, total lesion volume | Lesion analysis | −0.34** | −0.21 [#] | −0.40*** |
| | | FA analysis | 0.41*** | 0.33** | 0.53*** |
| | | | | | |
| Non-semantic control tasks | Repetition score, number score, MMSE, total lesion volume | Lesion analysis | −0.38** | −0.29* | −0.35** |
| | | FA analysis | 0.42*** | 0.37** | 0.47*** |
| | MMSE, total lesion volume | Lesion analysis (repetition) | 0.02 | 0.21 [#] | 0.08 |
| | | FA analysis (repetition) | 0.05 | −0.08 | 0.02 |
| | | Lesion analysis (number) | −0.12 | 0.02 | −0.01 |
| | | FA analysis (number) | 0.03 | 0 | −0.09 |
| | | | | | |
| | | | | | |

Behavioural index of all analyses are the semantic composite score, except those for the last four rows, which are presented in parentheses.

[#] $P < 0.10$; * $P < 0.05$; ** $P < 0.01$; *** $P < 0.001$ (two-tailed test).

MMSE = Mini-Mental State Examination (Folstein *et al.*, 1975) score; Lesion analysis = lesion percentage–behaviour analysis; FA analysis = fractional anisotropy–behaviour analysis.

total lesion volume values (total number of lesioned voxels across the whole brain) as covariates.

Types of brain damage

The patients included in the study presented with various types of brain damage. To ensure that the semantic-tract association effect we observed was not secondary to the influence of disease type, we carried out partial correlations between patients' semantic composite scores and lesion percentages or the tracts' mean fractional anisotropy values, with lesion type, MMSE scores and total lesion volume values as covariates. Lesion type was coded as 1 for stroke, 2 for trauma and 3 for others. Additionally, we also obtained the correlation between semantic scores and lesion percentages and mean fractional anisotropy values in each tract only for the 66 patients with stroke, and, in a separate analysis, only for the 25 patients with stroke in the left hemisphere, with MMSE scores and total lesion volume values as covariates.

Effects of grey matter lesion

To elucidate whether effects of white matter tracts could be accounted for by structural grey matter lesions (or preservation) we further performed the following analyses. We first checked whether the lesion percentage in the semantics-relevant regions correlated with semantic

deficits; then examined whether the white matter tracts of interest had effects on semantic processing above and beyond these grey matter lesioned regions by performing partial correlations between semantic composite scores and lesion percentages or mean fractional anisotropy values on these tracts, covarying the lesion percentages of each semantics-relevant grey matter region, the MMSE scores and total lesion volume values. The reverse partial correlation was also conducted, i.e. examined the effects of grey matter regions while covarying the white matter tract values. The semantics-relevant grey matter regions were derived from our previous results in Wei *et al.* (2012, Fig. 3 and Table 2), including significant clusters in dorsomedial prefrontal cortex, left inferior frontal gyrus, left middle temporal gyrus, left medial temporal lobe, posterior cingulate gyrus, right middle temporal gyrus and ventromedial prefrontal cortex. We chose the regions obtained from this study because they converge well with those reported in a meta-analysis study on semantic processing (Binder *et al.*, 2009) and because the specific result values are readily available. Furthermore, the selection of these regions has the advantage that, unlike some other studies with predefined regions of interest (Schwartz *et al.*, 2009; Pobric *et al.*, 2010), they were obtained on the basis of a whole brain analysis. Each region was treated as an independent binary cluster and the lesion percentage of each patient was obtained.

Non-semantic control tasks

To explore whether the semantics-related tracts were (relatively) specific to object semantic processing, we examined the association between these tracts (lesion percentage and fractional anisotropy) and two non-semantic control tasks. For each tract, oral repetition and number task scores were each correlated with the lesion percentages or mean fractional anisotropy values in all patients, with MMSE scores and total lesion volume values as covariates. We further examined whether the semantic effect was significant over and above any potential effects of these control tasks by a partial correlation analysis between semantic composite scores and lesion percentages or fractional anisotropy values, with the control task scores, MMSE scores and total lesion volume values as covariates.

Results

Behavioural and imaging analyses

The raw behaviour mean accuracies of the 76 patients in the three semantic tasks were: oral picture naming, $71 \pm 28\%$ (mean \pm SD); oral sound naming, $52 \pm 29\%$; and picture associative matching, $86 \pm 11\%$. Those of healthy control subjects were $97 \pm 3\%$, $82 \pm 11\%$ and $94 \pm 4\%$, respectively. The regression models built on the basis of healthy sample group were the following: oral picture naming, Y (predicted accuracy) = $0.9975 - 0.0008 \times X1$ (age) $- 0.0100 \times X2$ (gender) $+ 0.0011 \times X3$ (education); oral sound naming, $Y = 1.1029 - 0.0061 \times X1 - 0.0246 \times X2 + 0.0025 \times X3$; picture associative matching, $Y = 0.8947 - 0.0000 \times X1 + 0.0019 \times X2 + 0.0038 \times X3$. The derived estimates for patients performances on the basis of these regression models were the following: oral picture naming, $97 \pm 1\%$; oral sound naming, $85 \pm 8\%$; and picture associative matching, $94 \pm 1\%$. The normalized t scores of patients were -9.18 ± 9.94 , -3.22 ± 2.76 and -1.98 ± 2.65 , respectively.

The lesion distribution of the 76 patients is presented in Fig. 1. All white matter tracts except for three (left cingulum gyrus, left cingulum hippocampus and right cingulum hippocampus) had more than five patients with lesions. Five tracts [left anterior thalamic radiation (ATR), left corticospinal tract, left IFOF, left superior longitudinal fasciculus, and forceps minor] were damaged in $>50\%$ of the patients and five other tracts (right ATR, right corticospinal tract, right IFOF, left inferior longitudinal fasciculus, and left uncinate fasciculus) had lesions in 30–50% of the patients (Table 1).

Tracts correlated with semantic deficits

Lesion–behaviour correlation

As presented in Table 1 and Fig. 2, the lesion percentages of the following three tracts significantly correlated negatively with all three semantic tasks: left IFOF, left ATR, left uncinate fasciculus (corrected P -values < 0.05). In addition, the lesion percentage of left superior longitudinal fasciculus correlated negatively with oral picture naming performance and oral sound naming performance (corrected P -values < 0.001). The lesion percentage of right corticospinal tract correlated positively with the performance of these

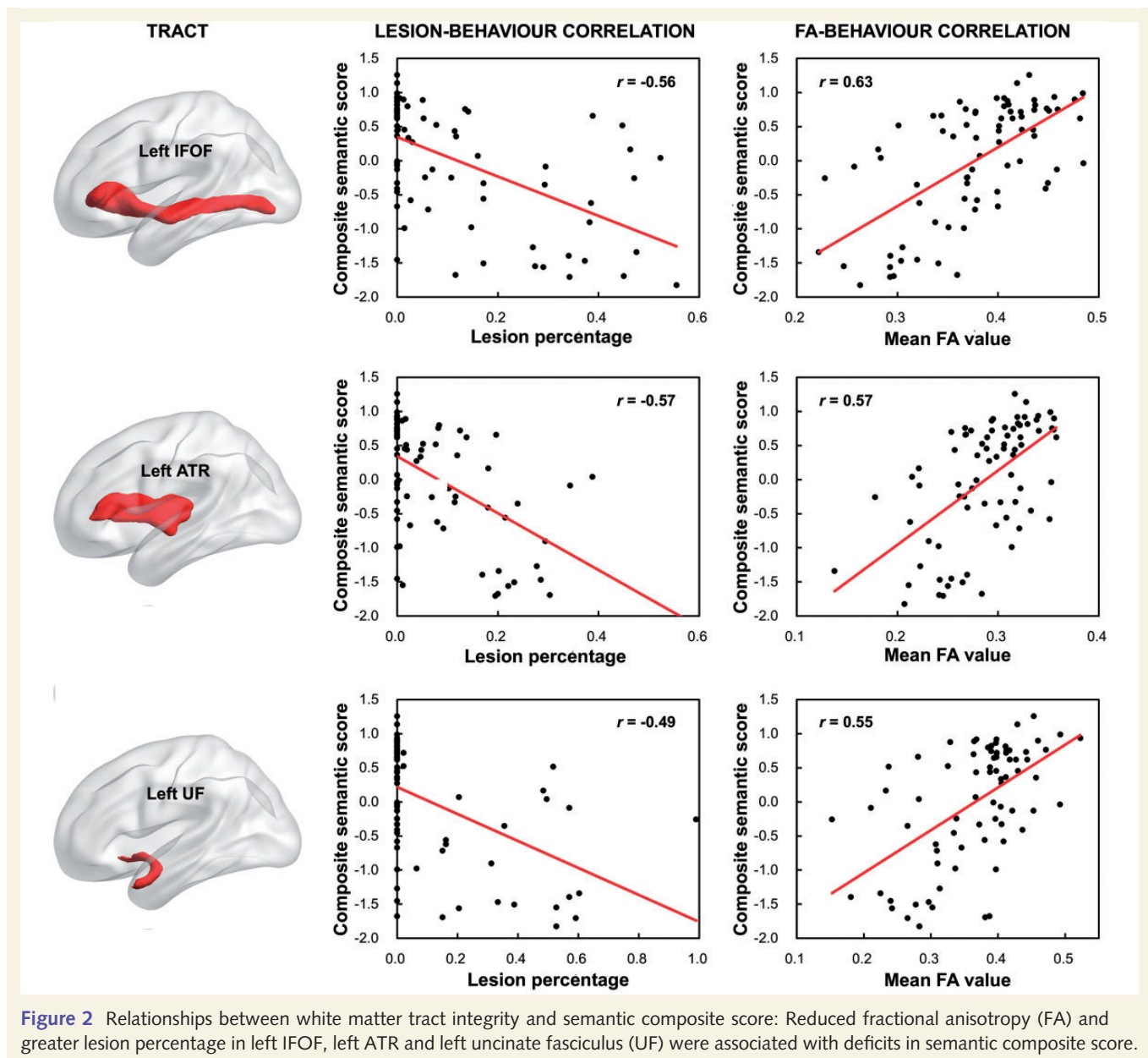
two oral tasks (corrected P -values < 0.05). The lesion percentage of all these five tracts, as well as right IFOF, significantly correlated with the semantic composite score (corrected P -values < 0.01), with the lesion effects of left hemisphere tracts being negative and of right hemisphere being positive. Highly similar patterns of results were obtained when raw accuracy was used for patients' behaviour index (with demographic properties partialled out) rather than normalized t -score (Supplementary Table 3), or when only the 66 stroke patients were analysed (Supplementary Table 5).

Fractional anisotropy–behaviour correlation

We found that the mean fractional anisotropy values of left IFOF, left ATR and left uncinate fasciculus, significantly correlated positively with all three semantic tasks (corrected P -values < 0.05 ; Table 1 and Fig. 2). In addition, the mean fractional anisotropy of left corticospinal tract, left inferior longitudinal fasciculus and left superior longitudinal fasciculus correlated positively with oral naming performance (corrected P -values < 0.001); left corticospinal tract and left superior longitudinal fasciculus correlated positively with oral object sound naming performance (corrected P -values < 0.001). The mean fractional anisotropy of a series of tracts on the right hemisphere were negatively correlated with oral naming performances (right ATR, right corticospinal tract, right IFOF, right superior longitudinal fasciculus and right uncinate fasciculus with picture naming, and those of right ATR, right corticospinal tract and right IFOF and right superior longitudinal fasciculus with sound naming; corrected P -values < 0.05). The mean fractional anisotropy value of all these tracts except for right IFOF, right superior longitudinal fasciculus and right uncinate fasciculus significantly correlated with the semantic composite score (corrected P -values < 0.05). A highly similar pattern of results was obtained when raw accuracy was used for patient's behaviour index (with demographic variables partialled out) rather than normalized t -score (Supplementary Table 3). When only the 66 stroke patients were analysed, all the results were replicated except for the effect of left uncinate fasciculus in the picture associative matching task, which was no longer significant although in the same direction ($r = 0.31$, $P = 0.21$, Supplementary Table 5).

Effects of fractional anisotropy beyond lesion measures

The highly convergent results in the lesion–behaviour and fractional anisotropy–behaviour correlation analyses invite the question as to whether these two measures reflect the same (lesion) effect. Indeed, the two measures were negatively correlated ($r = -0.55$, $P < 0.001$), such that the greater the lesion, the lower the mean fractional anisotropy. Nonetheless, for all three tracts showing significant effects in the fractional anisotropy–behaviour correlation (left IFOF, left ATR and left uncinate fasciculus), even after their lesion percentages were controlled for, their mean fractional anisotropy values still significantly correlated with the semantic composite scores (left IFOF: partial $r = 0.37$, $P < 0.002$; left ATR: partial $r = 0.35$, $P < 0.002$; left uncinate fasciculus: partial $r = 0.31$, $P < 0.007$). When white matter voxels with lesions were excluded from the analyses, the correlation between the mean fractional anisotropy of the remaining intact voxels and semantic composite scores was also significant (left



IFOF: $r = 0.49$, $P < 0.00001$; left ATR: $r = 0.54$, $P < 0.00001$; left uncinat fasciculus: $r = 0.46$, $P < 0.0001$).

Assessment of unique contribution of the relevant white matter tracts with regression analyses

We used multiple regression to specifically test whether each of the three tracts shown to be associated with semantic processing in the above correlation analyses made unique contributions beyond the other tracts by entering two tracts first and considering the effects of the third tract in a second step. When lesion percentage was considered, the left ATR showed a significant unique effect as indicated by the fact that it had significant predictive power for semantic composite scores (r^2 change = 0.06, $P < 0.02$) after controlling for the contribution of left IFOF and left uncinat fasciculus. Left IFOF did not show significantly

additional contribution beyond the effects of left ATR and left uncinat fasciculus, and neither did left uncinat fasciculus relative to left IFOF and left ATR. When mean fractional anisotropy was considered, the left IFOF showed a marginally significant unique effect for semantic composite scores (r^2 change = 0.03, $P < 0.07$) after controlling for the contribution of left ATR and left uncinat fasciculus. Left ATR did not show a significantly additional contribution beyond the effects of left IFOF and left uncinat fasciculus, and neither did left uncinat fasciculus relative to left IFOF and left ATR.

Summary

The integrity of left IFOF, left ATR, and left uncinat fasciculus were found to correlate significantly with performance across all semantic tasks in our patient group. The fractional anisotropy

measure showed additional effects beyond the lesion measure. In the regression model, left ATR showed significant unique effects in predicting semantic performance beyond the other two tracts in the lesion analyses, and left IFOF showed marginally unique effects in the fractional anisotropy analyses. No unique contributions of uncinat fasciculus above the other two tracts were observed in either analysis. The overall regression results indicate that the effects of these tracts may be correlated and our data set does not show strong distinctions among them. We therefore included all three tracts in further analyses.

Validating the semantics: relevance of the observed tracts

The above analyses revealed that the integrity of left IFOF, left ATR, and left uncinat fasciculus significantly predicts semantic processing ability in our patients. To further verify that the three white matter fibres are relevant for semantic processing, we carried out the control analyses below, in which normalized semantic composite *t*-scores were used for simplicity. The results are shown in Table 2. A highly similar pattern of results was obtained when raw accuracy of patients' performance was used with demographic variables partialled out (Supplementary Table 4).

Overall severity and total lesion volume

The semantic composite scores based on the three semantic tasks showed significant correlations with MMSE scores ($r = 0.80$, $P < 0.0001$) and total lesion volume values ($r = -0.22$, $P < 0.05$). When factoring out these two confounding variables, the semantic composite scores remained significantly correlated with lesion percentages (left IFOF: partial $r = -0.37$, $P < 0.002$; left ATR: partial $r = -0.25$, $P < 0.03$; left uncinat fasciculus: partial $r = -0.34$, $P < 0.004$) and with mean fractional anisotropy values of the three tracts of interest (left IFOF: partial $r = 0.42$, $P < 0.0003$; left ATR: partial $r = 0.36$, $P < 0.002$; left uncinat fasciculus: partial $r = 0.47$; $P < 0.00003$).

Types of brain damage

Lesion type index was not correlated with semantic composite scores ($r = 0.04$, $P = 0.73$). When we included this index in addition to MMSE scores and total lesion volume values as covariates, the correlation between the semantic composite scores and the integrity measures of left IFOF, left ATR and left uncinat fasciculus were still all significant (lesion percentage: left IFOF, partial $r = -0.39$, $P < 0.0007$; left ATR, partial $r = -0.28$, $P < 0.02$; left uncinat fasciculus, partial $r = -0.35$, $P < 0.003$; mean fractional anisotropy, left IFOF: partial $r = 0.43$, $P < 0.0002$; left ATR, partial $r = 0.36$, $P < 0.002$; left uncinat fasciculus, partial $r = 0.46$, $P < 0.00004$). The pattern held up well for the correlation with MMSE scores and total lesion volume values as covariates when we considered only the 66 stroke patients (lesion percentage: left IFOF, partial $r = -0.49$, $P < 0.00005$; left ATR, partial $r = -0.34$, $P < 0.007$; left uncinat fasciculus, partial $r = -0.43$, $P < 0.0004$; mean fractional anisotropy: left IFOF, partial $r = 0.42$, $P < 0.0006$; left ATR, partial $r = 0.39$, $P < 0.002$; left uncinat fasciculus, partial $r = 0.42$, $P < 0.0005$); and when we considered only the 25 patients with left

hemisphere strokes (lesion percentage: left IFOF, partial $r = -0.57$, $P < 0.005$; left ATR, partial $r = -0.22$, $P = 0.32$; left uncinat fasciculus, partial $r = -0.41$, $P < 0.05$; mean fractional anisotropy: left IFOF, partial $r = 0.53$, $P < 0.008$; left ATR, partial $r = 0.49$, $P < 0.02$; left uncinat fasciculus, partial $r = 0.53$, $P < 0.008$).

Influence of grey matter lesions

We examined the contribution of grey matter more specifically by considering the grey matter regions that are relevant to semantic processing obtained from Wei *et al.* (2012). Lesion percentages of most grey matter regions in the semantic network, except for posterior cingulate gyrus and ventromedial prefrontal cortex, were significantly or marginally significantly correlated with the semantic composite score ($r = -0.37$ to 0.21 , P -values < 0.07). Importantly, after covarying the effect of lesion percentages of these grey matter regions, the MMSE scores, and total lesion volume values, the correlations between the semantic composite scores and the lesion percentages of the left IFOF, left ATR and left uncinat fasciculus remained significant or marginally significant (lesion percentage: left IFOF, partial $r = -0.34$, $P < 0.004$; left ATR, partial $r = -0.21$, $P = 0.09$; left uncinat fasciculus: partial $r = -0.40$, $P < 0.0008$). The same pattern was observed when mean fractional anisotropy values were considered (left IFOF, partial $r = 0.41$, $P < 0.0006$; left ATR, partial $r = 0.33$, $P < 0.007$; left uncinat fasciculus, partial $r = 0.53$, $P < 0.000005$). Note that when covarying out lesion percentages of the tracts, MMSE scores, and total lesion volume scores, the correlation between lesion percentages in these grey matter regions and semantic composite scores was no longer significant (P -values > 0.07), except for left inferior frontal gyrus (partial $r = -0.26$, $P < 0.03$). Furthermore, when covarying out mean fractional anisotropy values of the tracts, MMSE scores, and total lesion volume scores, the correlation between lesion percentages in these grey matter regions and semantic composite scores was no longer significant (P -values > 0.06), except for left middle temporal gyrus (partial $r = 0.26$, $P < 0.03$).

Non-semantic control tasks

For the two control tasks, neither the oral repetition scores nor the number scores showed significant correlation with integrity of left IFOF, left ATR or left uncinat fasciculus, after MMSE scores and total lesion volume values were regressed out (lesion percentage: partial $r = -0.12$ to 0.21 , P -values > 0.07 ; mean fractional anisotropy: partial $r = -0.09$ to 0.05 , P -values > 0.40). When these control tasks, MMSE scores and total lesion volume values were treated as covariates, the semantic composite scores still significantly correlated with the integrity of left IFOF, left ATR and left uncinat fasciculus (lesion percentage: left IFOF, partial $r = -0.38$, $P < 0.002$; left ATR: partial $r = -0.29$, $P < 0.02$; left uncinat fasciculus: partial $r = -0.35$, $P < 0.003$; mean fractional anisotropy: left IFOF, partial $r = 0.42$, $P < 0.0003$; left ATR, partial $r = 0.37$, $P < 0.002$; left uncinat fasciculus, partial $r = 0.47$, $P < 0.00004$). In other words, left IFOF, left ATR and left uncinat fasciculus are not merely related to cognitive processing in general but are (relatively) specific to object semantic processing.

Discussion

Using behavioural, structural and diffusion MRI data of 76 brain-damaged patients, we observed that the lesion volume and fractional anisotropy value of left IFOF, left ATR and left uncinate fasciculus significantly correlated with semantic impairment severity on tasks across different modalities of inputs (visual or auditory stimuli) or outputs (oral production or associative judgement). These relationships remained even when we controlled for a wide range of potential confounding variables, including overall cognitive state, whole lesion volume and type of brain damage. Furthermore, these effects cannot be fully explained by relevant grey matter involvement, and were (relatively) specific to object semantic processing as no correlation with performance on non-object-semantic control tasks (oral repetition and number tasks) were observed.

One can envision several ways in which a connection functions in semantic processing, including: (i) to bind different aspects of semantic knowledge (e.g. knowledge about sensory and motor properties); (ii) to connect semantic knowledge with various other cognitive functions for a given task context (e.g. verbal system, episodic memory, executive control); and (iii) to establish a larger network whose overall pattern/state underlies semantic processing. The functions that our observed tracts serve in semantic processing need to be understood in the context of the regions they connect, as discussed below.

Left inferior fronto-occipital fasciculus

Our results showing a causal role of left IFOF in semantic processing are in line with a series of previous studies (Duffau *et al.*, 2002, 2005, 2009; Mandonnet *et al.*, 2007; Duffau, 2008; Acosta-Cabronero *et al.*, 2010, 2011; de Zubizaray *et al.*, 2011; Schwindt *et al.*, 2011) and add important evidence that clarifies the interpretation of those studies. Duffau and colleagues have shown that temporary dysfunction of the left IFOF induced by intraoperative electrical stimulation led patients to make semantic errors in oral picture naming (Duffau *et al.*, 2002, 2005, 2009; Duffau, 2008; Mandonnet *et al.*, 2007). Although semantic errors can originate from either the semantic system or the lexical retrieval process (Caramazza and Hillis, 1990; Cloutman *et al.*, 2009), our finding that IFOF lesions are associated with deficits not only in verbal tasks (object picture naming and object sound naming) but also in a non-verbal task (picture associative matching) suggest that left IFOF is necessary for semantic processing (without excluding the possibility that it is also necessary for lexical retrieval).

What kind of mechanism underlies the functioning of left IFOF in semantic processing? The IFOF, the longest associative bundle, was recognized early, yet only recently has its precise anatomical structure been elucidated. Through dissection of post-mortem brains and diffusion tensor imaging methods with healthy 'in vivo' brains, Martino *et al.* (2010) and Sarubbo *et al.* (2013) observed that the IFOF includes two subcomponents. The superficial layer connects the superior parietal lobule, the occipital extrastriate cortex, Wernicke's territories and fusiform gyrus to the inferior frontal gyrus (pars triangularis and opercularis), through

the extreme and external capsules. The deep layer has three portions: a posterior portion connecting the superior parietal lobule/occipital extrastriate cortex/fusiform gyrus to the dorsolateral prefrontal cortex /middle frontal gyrus; a middle portion connecting the superior parietal lobule to the middle frontal gyrus/lateral orbito-frontal cortex; an anterior portion connecting the occipital extra-striate cortex/fusiform gyrus to the basal orbitofrontal cortex and partially overlapping with the uncinate fasciculus.

Turken and Dronkers (2011) reported that IFOF connects posterior middle temporal gyrus and anterior inferior frontal cortex [Brodmann area (BA)47]. They showed this by carrying out fibre-tracking analyses using seeds that have been shown to be relevant to semantic processing in voxel based lesion-symptom mapping analyses: middle temporal gyrus, anterior superior temporal gyrus/BA22, BA47, BA46 and superior temporal sulcus/BA39. Left posterior middle temporal gyrus and inferior frontal cortex were also the two grey matter regions whose extent of damage correlated with semantic scores above and beyond the effects of three white matter tracts in our analyses, suggesting the particular significance of these two regions along IFOF. Given that posterior middle temporal cortex, adjacent Wernicke's areas, and inferior frontal regions are consistently shown to be involved in language comprehension and production tasks (Hillis *et al.*, 2001; Vigneau *et al.*, 2006; Binder *et al.*, 2009), this section of the surface layer of the IFOF pathway may be specifically involved in bridging semantic memory with the verbal system.

Interestingly, fusiform gyrus and dorsolateral prefrontal cortex are activated by visual, auditory and tactile object information (Kassuba *et al.*, 2011). Therefore, the deeper layer of IFOF may also be important for object semantic processing, serving a binding function of different modalities of object information. The exact functions of the subcomponents of IFOF that anatomically connect these different grey matter structures remain to be uncovered.

Left anterior thalamic radiation

Our results also revealed that left ATR is necessary for semantic processing. ATR is a major white matter tract projection from the thalamus that penetrates the anterior limb of the internal capsule, carrying reciprocal connections from the hypothalamus and limbic structures to the frontal cortex, including Broca's area (pars triangularis and pars opercularis). Its abnormality has been reported to be associated with autism (Cheng *et al.*, 2010; Tan *et al.*, 2010; Cheon *et al.*, 2011), impaired episodic memory and executive function in late-life depression (Sexton *et al.*, 2012), and schizophrenia (Mamah *et al.*, 2010).

To our knowledge, our study provides the first direct empirical evidence for the ATR's crucial role in the semantic system, perhaps because previous studies tended not to include it as a tract of prior interest. Nonetheless, there is evidence that the two major regions it connects—inferior frontal gyrus and thalamus—might be involved in semantic processing. As reviewed above, the role of inferior frontal gyrus in semantic processing has been commonly accepted. The thalamus has been found to be relevant for a variety of cognitive functions such as episodic memory, executive function, as well as language (Vermeer *et al.*, 2003; Sexton *et al.*,

2012; for a review see Crosson, 2013). Neuropsychological studies have found that dominant thalamus infarct leads to thalamus aphasia, manifesting three main features: (i) fluent output with mainly semantic paraphasias (Crosson, 1984); (ii) auditory-verbal comprehension impairment; and (iii) preserved repetition (Crosson, 1992). This profile fits with deficits to the semantic system or the semantics-driven lexical access process (Crosson, 1984, 1992; Nadeau and Crosson, 1997; Radanovic and Scaff, 2003; Marien *et al.*, 2005; Cox and Heilman, 2011). Moreover, patients with thalamus aphasia have been reported to show semantic category-specific deficits, such as selective impairment for proper nouns (Lucchelli and De Renzi, 1992; Moreaud *et al.*, 1995) or for medical objects and conditions (Crosson *et al.*, 1997). Functional imaging studies with healthy participants have shown that the thalamus is activated in a semantic associative matching (object name and feature name) task (Kraut *et al.*, 2002, 2003; Assaf *et al.*, 2006), leading to the proposal that the thalamus is involved in feature binding for semantic object memory (Hart *et al.*, 2007). Our findings further demonstrate that the anatomical connection between inferior frontal gyrus and thalamus is necessary for semantic processing, indicating their roles in an intrinsic semantic network. At this stage, however, we can only speculate about the exact function this particular pathway serves in semantic processing. It is worth noting that both thalamus and inferior frontal gyrus have also been linked to executive control, thus it would be worth examining whether the ATR is particularly important in controlling semantic information for a given task context.

Left uncinate fasciculus

de Zubicaray *et al.* (2011) reported that the fractional anisotropy value of left uncinate fasciculus, the tract connecting the anterior temporal lobe with the orbitofrontal cortex, in addition to left IFOF, correlated with semantic principal component analysis scores in healthy older subjects. Here, we also observed that the lesion volumes and fractional anisotropy values of the left uncinate fasciculus correlated with semantic deficits. The uncinate fasciculus's effect in semantic processing is compelling given that anterior temporal lobe has been suggested to be the core binding site for different modalities of semantic knowledge (Patterson *et al.*, 2007; but see Bi *et al.*, 2011). It is conceivable that the uncinate fasciculus is important in the retrieval of context-relevant semantic properties for a given context/task, as orbitofrontal cortex has been implicated in the executive control system. Note that Duffau *et al.* (2009) showed that in patients with low-grade glioma resection stimulating the uncinate fasciculus never induced any language disturbance, whereas stimulating the IFOF and the arcuate fasciculus elicited semantic errors and phonological errors, respectively. Furthermore, all patients recovered after a transient postoperative language deficit, despite the removal of at least part of the uncinate fasciculus. Such negative evidence might be due to anatomical and/or functional reorganization in patients with slow-growing tumours (Thiel *et al.*, 2005).

Besides the white matter tracts examined here, the extreme capsule, the tract connecting Broca's area with Wernicke's area, has been suggested to be involved in semantic processing. Saur *et al.* (2008, 2010) tracked fibres among regions showing

functional connectivity during verbal semantic tasks and found that all tracked fibres went through the extreme capsule. Rolheiser *et al.* (2011) found that fractional anisotropy values in extreme capsule in stroke patients correlate with lexical-semantic task performance. The John Hopkins University white-matter tractography atlas we adopted here did not include an extreme capsule tract and, therefore, we could not examine its role in semantic processing. Nonetheless, as discussed above, IFOF, at least the superficial layer, connects the posterior regions to the inferior frontal gyrus through the extreme and external capsules. Whether the effects of extreme capsule and IFOF can be uncoupled warrants further investigation.

Several further caveats should be considered. First, we did not observe meaningful effects of the right hemisphere tracts in either verbal or non-verbal semantic tasks. Previous patient studies have reported mixed results about the lateralization of non-verbal semantics, with some reporting a right temporal lobe effect (Tranel *et al.*, 1997; Gainotti, 2012), some a bilateral effect (Patterson *et al.*, 2007), and some a left hemisphere effect (Warrington and Taylor, 1975). Damasio *et al.* (2004) observed that the lateralization might depend on object categories, with living things tending to be represented bilaterally and tools to be left lateralized (Brambati *et al.*, 2006; Anzellotti *et al.*, 2011). Further studies considering finer categorical distinctions and task differences are needed for a more precise understanding of the relative contributions of the two hemispheres in the representation of meaning. Second, the spurious effects of the right hemisphere, especially for the oral naming tasks (that is, larger lesions associated with better performance), might be because right hemisphere lesions tended to correlate negatively with left hemisphere lesions ($r = -0.30$, $P = 0.009$), which have a causal effect on semantic performance. Third, it should be noted that our analyses here were constrained by the lesion distribution in the patient groups. Consistent with the literature (Schwartz *et al.*, 2009), our patients tended to have lesions in the territory of the middle cerebral artery and thus relevant tracts would have larger variances in the data set, leading to greater statistical power. The negative effects of tracts with small numbers of lesioned patients should therefore be interpreted with caution. Finally, although we have discussed the potential function of each individual tract, it is theoretically possible that the individual tracts investigated do not have a specific function and it is the overall pattern of multiple tracts that matters for semantic processing. Here, too, further studies considering parameters on a network level are needed to address this issue.

Conclusion

We identified three major white matter tracts necessary for the normal functioning of the semantic system: the left IFOF connecting many grey matter regions that have been implicated in semantic processing, such as ventral posterior lateral temporal regions and frontal regions; the left ATR connecting the inferior frontal cortex with thalamus; and the left uncinate fasciculus connecting the anterior temporal lobe with the orbitofrontal cortex. The lesion volume and mean fractional anisotropy values of these three tracts significantly predict the severity of semantic deficit in patients, as

measured by the joint performance in three semantic tasks across visual and auditory input modalities and verbal and non-verbal output modalities. These results underscore the causal role of the left IFOF, ATR and uncinate fasciculus in semantic processing, providing direct evidence for (part of) the anatomical skeleton of the semantic network. Our study highlights the need for further investigations about the more specific mechanisms and functions of these white matter tracts, and the type of information conveyed by the various components of these tracts that anatomically connect different grey matter regions.

Acknowledgements

We thank Luping Song for participant recruitment, Ruiwang Huang and Litao Zhu for help with imaging methodology, Xiaodong Liu for help with statistical analysis and all BNU-CNLab members for data collection and imaging preprocessing, in particular Yangwen Xu, Fangson Liu and Jing Chen. We are also grateful to all research participants.

Funding

This study was funded by 973 Program (2013CB837300), Major Project of National Social Science Foundation (11&ZD186), NSFC (31171073; 31222024; 31271115; 81030028; 31221003; 31000499), Beijing Natural Science Foundation (Z111107067311036), NCET (12-0055; 12-0065), and the National Science Fund for Distinguished Young Scholars (81225012, YH). A.C. was supported by the Fondazione Cassa di Risparmio di Trento e Rovereto.

Supplementary material

Supplementary material is available at *Brain* online.

References

Acosta-Cabronero J, Patterson K, Fryer TD, Hodges JR, Pengas G, Williams GB, et al. Atrophy, hypometabolism and white matter abnormalities in semantic dementia tell a coherent story. *Brain* 2011; 134: 2025–35.

Acosta-Cabronero J, Williams GB, Pengas G, Nestor PJ. Absolute diffusivities define the landscape of white matter degeneration in Alzheimer's disease. *Brain* 2010; 133: 529–39.

Anzellotti S, Mahon BZ, Schwarzbach J, Caramazza A. Differential activity for animals and manipulable objects in the anterior temporal lobes. *J Cogn Neurosci* 2011; 23: 2059–67.

Assaf M, Calhoun VD, Kuzu CH, Kraut MA, Rivkin PR, Hart J Jr, et al. Neural correlates of the object-recall process in semantic memory. *Psychiatry Res* 2006; 147: 115–26.

Basser PJ, Pierpaoli C. Microstructural and physiological features of tissues elucidated by quantitative-diffusion-tensor MRI. *J Magn Reson B* 1996; 111: 209–19.

Bates E, Wilson SM, Saygin AP, Dick F, Sereno MI, Knight RT, et al. Voxel-based lesion-symptom mapping. *Nat Neurosci* 2003; 6: 448–50.

Bi Y, Wei T, Wu C, Han Z, Jiang T, Caramazza A. The role of the left anterior temporal lobe in language processing revisited: evidence from an individual with ATL resection. *Cortex* 2011; 47: 575–87.

Binder JR, Desai RH, Graves WW, Conant LL. Where is the semantic system? A critical review and meta-analysis of 120 functional neuroimaging studies. *Cereb Cortex* 2009; 19: 2767–96.

Brambati SM, Myers D, Wilson A, Rankin KP, Allison SC, Rosen HJ, et al. The anatomy of category-specific object naming in neurodegenerative diseases. *J Cogn Neurosci* 2006; 18: 1644–53.

Caramazza A, Hillis AE. Where do semantic errors come from? *Cortex* 1990; 26: 95–122.

Catani M, ffytche DH. The rises and falls of disconnection syndromes. *Brain* 2005; 128 (Pt 10): 2224–39.

Cheng Y, Chou KH, Chen IY, Fan YT, Decety J, Lin CP. Atypical development of white matter microstructure in adolescents with autism spectrum disorders. *NeuroImage* 2010; 50: 873–82.

Cheon KA, Kim YS, Oh SH, Park SY, Yoon HW, Herrington J, et al. Involvement of the anterior thalamic radiation in boys with high functioning autism spectrum disorders: a Diffusion Tensor Imaging study. *Brain Res* 2011; 1417: 77–86.

Cloutman L, Gottesman R, Chaudhry P, Davis C, Kleinman JT, Pawlak M, et al. Where (in the brain) do semantic errors come from? *Cortex* 2009; 45: 641–9.

Cox DE, Heilman KM. Dynamic-intentional thalamic aphasia: a failure of lexical-semantic self-activation. *Neurocase* 2011; 17: 313–7.

Crawford JR, Garthwaite PH. Comparing patients' predicted test scores from a regression equation with their obtained scores: a significance test and point estimate of abnormality with accompanying confidence limits. *Neuropsychology* 2006; 20: 259–71.

Crosson AW. Subcortical functions in language and memory. New York: Guilford; 1992.

Crosson B. Role of the dominant thalamus in language: a review. *Psychol Bull* 1984; 96: 491–517.

Crosson B. Thalamic mechanisms in language: a reconsideration based on recent findings and concepts. *Brain Lang* 2013; 126: 73–88.

Crosson B, Moberg PJ, Boone JR, Rothi LJ, Raymer A. Category-specific naming deficit for medical terms after dominant thalamic/capsular hemorrhage. *Brain Lang* 1997; 60: 407–42.

Cui Z, Zhong S, Xu P, He Y, Gong G. PANDA: a pipeline toolbox for analyzing brain diffusion images. *Front Hum Neurosci* 2013; 7: doi: 10.3389/fnhum.2013.00042.

Damasio H, Tranel D, Grabowski T, Adolphs R, Damasio A. Neural systems behind word and concept retrieval. *Cognition* 2004; 92: 179–229.

de Zubicaray GI, Rose SE, McMahon KL. The structure and connectivity of semantic memory in the healthy older adult brain. *NeuroImage* 2011; 54: 1488–94.

Dronkers NF, Wilkins DP, Van Valin RD Jr, Redfern BB, Jaeger JJ. Lesion analysis of the brain areas involved in language comprehension. *Cognition* 2004; 92: 145–77.

Duffau H. The anatomo-functional connectivity of language revisited. New insights provided by electrostimulation and tractography. *Neuropsychologia* 2008; 46: 927–34.

Duffau H, Capelle L, Sichez N, Denvil D, Lopes M, Sichez JP, et al. Intraoperative mapping of the subcortical language pathways using direct stimulations. An anatomo-functional study. *Brain* 2002; 125: 199–214.

Duffau H, Gatignol P, Mandonnet E, Peruzzi P, Tzourio-Mazoyer N, Capelle L. New insights into the anatomo-functional connectivity of the semantic system: a study using cortico-subcortical electrostimulations. *Brain* 2005; 128 (Pt 4): 797–810.

Duffau H, Gatignol P, Moritz-Gasser S, Mandonnet E. Is the left uncinate fasciculus essential for language? A cerebral stimulation study. *J Neurol* 2009; 256: 382–9.

Folstein MF, Folstein SE, McHugh PR. "Mini-mental state". A practical method for grading the cognitive state of patients for the clinician. *J Psychiatr Res* 1975; 12: 189–98.

- Forster KI, Forster JC. DMDX: a windows display program with millisecond accuracy. *Behav Res Methods Instrum Comput* 2003; 35: 116–24.
- Gainotti G. The format of conceptual representations disrupted in semantic dementia: a position paper. *Cortex* 2012; 48: 521–9.
- Geschwind N. Disconnexion syndromes in animals and man. *Brain* 1965; 88: 237–94.
- Hart J Jr, Anand R, Zoccoli S, Maguire M, Gamino J, Tillman G, et al. Neural substrates of semantic memory. *J Int Neuropsychol Soc* 2007; 13: 865–80.
- Hillis AE, Wityk RJ, Tuffiash E, Beauchamp NJ, Jacobs MA, Barker PB, et al. Hypoperfusion of Wernicke's area predicts severity of semantic deficit in acute stroke. *Ann Neurol* 2001; 50: 561–6.
- Howard D, Patterson K. *Pyramids and palm trees test: a test of semantic access from words and pictures*. Bury St Edmunds, Suffolk: Thames Valley Test Company. 1992.
- Jefferies E, Patterson K, Ralph MA. Deficits of knowledge versus executive control in semantic cognition: insights from cued naming. *Neuropsychologia* 2008; 46: 649–58.
- Kassuba T, Klinge C, Holig C, Menz MM, Ptito M, Roder B, et al. The left fusiform gyrus hosts trisensory representations of manipulable objects. *NeuroImage* 2011; 56: 1566–77.
- Kim J, Lee SK, Lee JD, Kim YW, Kim DI. Decreased fractional anisotropy of middle cerebellar peduncle in crossed cerebellar diaschisis: diffusion-tensor imaging-positron-emission tomography correlation study. *AJNR Am J Neuroradiol* 2005; 26: 2224–8.
- Kraut MA, Calhoun V, Pitcock JA, Cusick C, Hart J Jr. Neural hybrid model of semantic object memory: implications from event-related timing using fMRI. *J Int Neuropsychol Soc* 2003; 9: 1031–40.
- Kraut MA, Kremen S, Segal JB, Calhoun V, Moo LR, Hart J Jr. Object activation from features in the semantic system. *J Cogn Neurosci* 2002; 14: 24–36.
- Lucchelli F, De Renzi E. Proper name anomia. *Cortex* 1992; 28: 221–30.
- Mahon BZ, Caramazza A. Concepts and categories: a cognitive neuropsychological perspective. *Annu Rev Psychol* 2009; 60: 27–51.
- Mamah D, Conturo TE, Harms MP, Akbudak E, Wang L, McMichael AR, et al. Anterior thalamic radiation integrity in schizophrenia: a diffusion-tensor imaging study. *Psychiatry Res* 2010; 183: 144–50.
- Mandonnet E, Nouet A, Gatignol P, Capelle L, Duffau H. Does the left inferior longitudinal fasciculus play a role in language? A brain stimulation study. *Brain* 2007; 130: 623–9.
- Marien P, Abutaleb J, Engelborghs S, De Deyn PP. Pathophysiology of language switching and mixing in an early bilingual child with subcortical aphasia. *Neurocase* 2005; 11: 385–98.
- Martin A. The representation of object concepts in the brain. *Annu Rev Psychol* 2007; 58: 25–45.
- Martino J, Brogna C, Robles SG, Vergani F, Duffau H. Anatomic dissection of the inferior fronto-occipital fasciculus revisited in the lights of brain stimulation data. *Cortex* 2010; 46: 691–9.
- Moreaud O, Pellat J, Charnallet A, Carbonnel S, Brennen T. [Deficiency in the reproduction and learning proper names after left tubero-thalamic ischemic lesion]. *Rev Neurol (Paris)* 1995; 151: 93–9.
- Nadeau SE, Crosson B. Subcortical aphasia. *Brain Lang* 1997; 58: 355–402; discussion 18–23.
- Oldfield RC. The assessment and analysis of handedness: the Edinburgh inventory. *Neuropsychologia* 1971; 9: 97–113.
- Patterson K, Nestor PJ, Rogers TT. Where do you know what you know? The representation of semantic knowledge in the human brain. *Nat Rev Neurosci* 2007; 8: 976–87.
- Pobric G, Jefferies E, Lambon Ralph MA. Category-specific versus category-general semantic impairment induced by transcranial magnetic stimulation. *Curr Biol* 2010; 20: 964–8.
- Radanovic M, Scaff M. Speech and language disturbances due to subcortical lesions. *Brain Lang* 2003; 84: 337–52.
- Rolheiser T, Stamatakis EA, Tyler LK. Dynamic processing in the human language system: synergy between the arcuate fascicle and extreme capsule. *J Neurosci* 2011; 31: 16949–57.
- Rudrauf D, Mehta S, Bruss J, Tranel D, Damasio H, Grabowski TJ. Thresholding lesion overlap difference maps: application to category-related naming and recognition deficits. *Neuroimage* 2008; 41: 970–84.
- Sarubbo S, De Benedictis A, Maldonado IL, Basso G, Duffau H. Frontal terminations for the inferior fronto-occipital fascicle: anatomical dissection, DTI study and functional considerations on a multi-component bundle. *Brain Struct Funct* 2013; 218: 21–37.
- Saur D, Kreher BW, Schnell S, Kummerer D, Kellmeyer P, Vry MS, et al. Ventral and dorsal pathways for language. *Proc Natl Acad Sci USA* 2008; 105: 18035–40.
- Saur D, Schelter B, Schnell S, Kratochvil D, Kupper H, Kellmeyer P, et al. Combining functional and anatomical connectivity reveals brain networks for auditory language comprehension. *NeuroImage* 2010; 49: 3187–97.
- Schwartz MF, Kimberg DY, Walker GM, Faseyitan O, Brecher A, Dell GS, et al. Anterior temporal involvement in semantic word retrieval: voxel-based lesion-symptom mapping evidence from aphasia. *Brain* 2009; 132 (Pt 12): 3411–27.
- Schwindt GC, Graham NL, Rochon E, Tang-Wai DF, Lobaugh NJ, Chow TW, et al. Whole-brain white matter disruption in semantic and nonfluent variants of primary progressive aphasia. *Hum Brain Mapp* 2013; 34: 973–84.
- Sexton CE, McDermott L, Kalu UG, Herrmann LL, Bradley KM, Allan CL, et al. Exploring the pattern and neural correlates of neuropsychological impairment in late-life depression. *Psychol Med* 2012; 42: 1195–202.
- Tan GC, Doke TF, Ashburner J, Wood NW, Frackowiak RS. Normal variation in fronto-occipital circuitry and cerebellar structure with an autism-associated polymorphism of CNTNAP2. *NeuroImage* 2010; 53: 1030–42.
- Thiel A, Habedank B, Winhuisen L, Herholz K, Kessler J, Haupt WF, Heiss WD. Essential language function of the right hemisphere in brain tumor patients. *Ann Neurol* 2005; 57: 128–31.
- Tranel D, Damasio H, Damasio AR. A neural basis for the retrieval of conceptual knowledge. *Neuropsychologia* 1997; 35: 1319–27.
- Turken AU, Dronkers NF. The neural architecture of the language comprehension network: converging evidence from lesion and connectivity analyses. *Front Syst Neurosci* 2011; 5: doi: 10.3389/fnsys.2011.00001.
- Vermeer SE, Hollander M, van Dijk EJ, Hofman A, Koudstaal PJ, Breteler MM, et al. Silent brain infarcts and white matter lesions increase stroke risk in the general population: the Rotterdam Scan Study. *Stroke* 2003; 34: 1126–9.
- Vigneau M, Beaucousin V, Herve PY, Duffau H, Crivello F, Houde O, et al. Meta-analyzing left hemisphere language areas: phonology, semantics, and sentence processing. *NeuroImage* 2006; 30: 1414–32.
- Warrington EK, Taylor AM. Two categorical stages of object recognition. *Perception* 1978; 7: 695–705.
- Wei T, Liang X, He Y, Zang Y, Han Z, Caramazza A, et al. Predicting conceptual processing capacity from spontaneous neuronal activity of the left middle temporal gyrus. *J Neurosci* 2012; 32: 481–9.
- Wilson SM, Galantucci S, Tartaglia MC, Rising K, Patterson DK, Henry ML, et al. Syntactic processing depends on dorsal language tracts. *Neuron* 2011; 72: 397–403.